

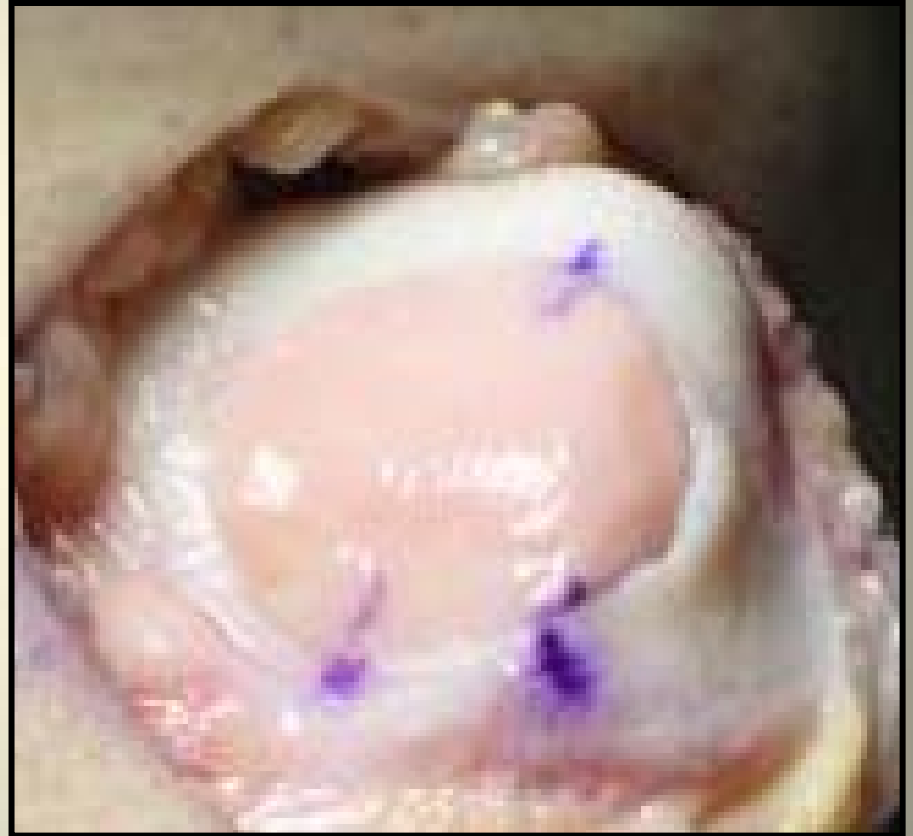Geometrical and Sizing Considerations for Biologic Resurfacing of the PFJ

focus on Osteochondral Allografts

Phil Davidson, MD
Heiden Davidson Orthopaedics
IPFSG San Diego, CA
July 2011

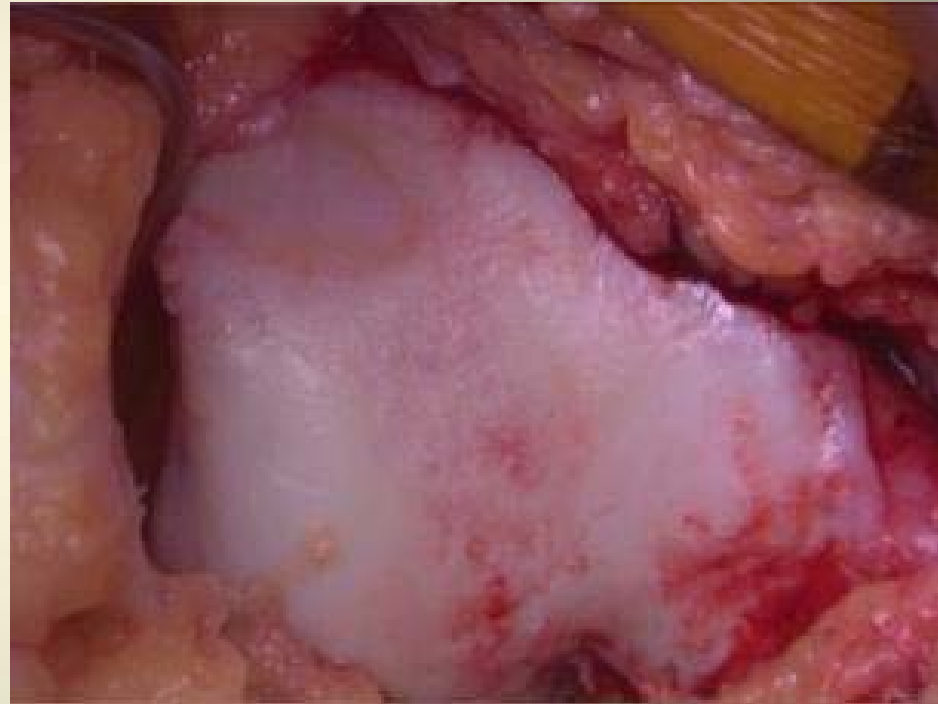Outline

- Geometric/Morphologic Variability
- Defining Goals
- Geometric Challenges
- Donor Issues
- Clinical scenarios
- Recommendations for Sizing OCA



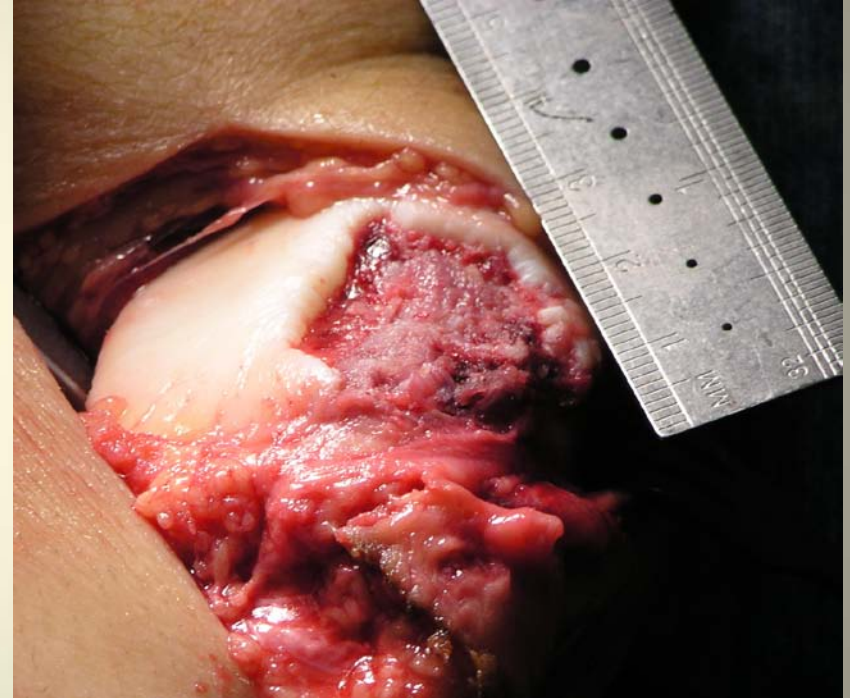
Geometric Variability

- Wide array of both “normal” and “pathologic”
- “Normals”
 - Both patella and FTG manifest variable curvatures, convexities and concavities
 - Concavity of FTG generally in the 4 and 5 mm range of height, with 4 being “shallow” and 5 “deeper”
 - Patella generally ovoid or cylindrical, variable height of ridge or radius of curvature



Morphologic Variability

- Pathologic – Traumatic or Atraumatic
 - Traumatic- much simpler as usually has relatively “normal” morphology
 - Atraumatic- more common in PFJ practice.
 - Relative degree of FTG hypoplasia, aplasia and malalignment/malrotation
 - Patella frequently has lateral facet dominance from chronic subluxation/lateralization

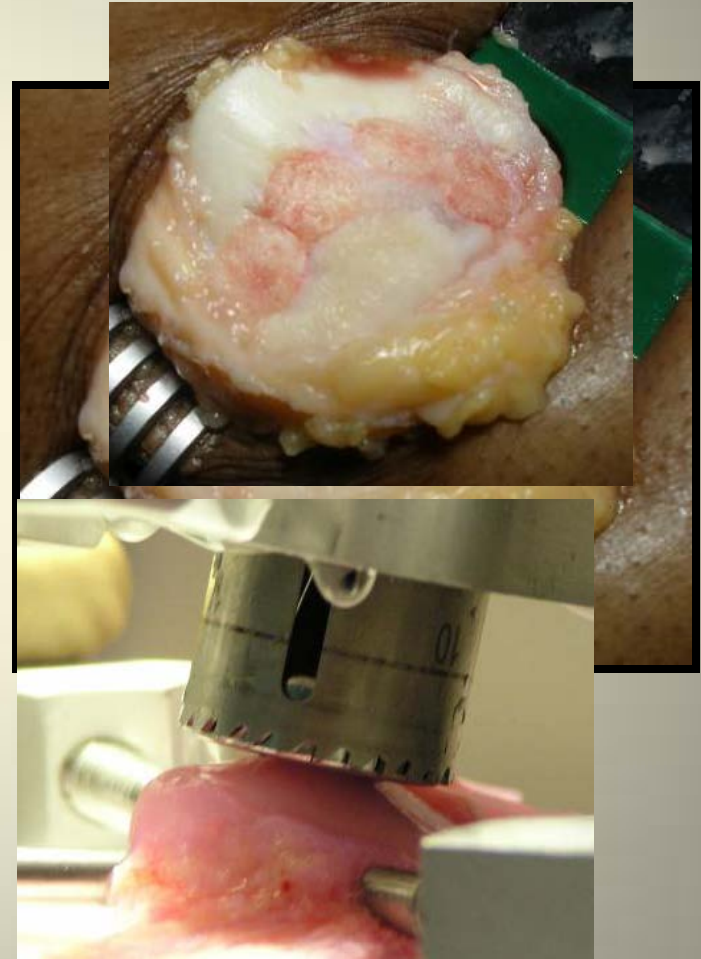


Defining Surgical Goals – biological restoration of PFJ

- Congruous, concentric restoration of hyaline cartilage
- Secure and stable with minimal fixation
- Simple and reproducible
- Allow early ROM and Weight Bearing
- Predictably good/excellent results with few complications or revisions needed
- Long lasting

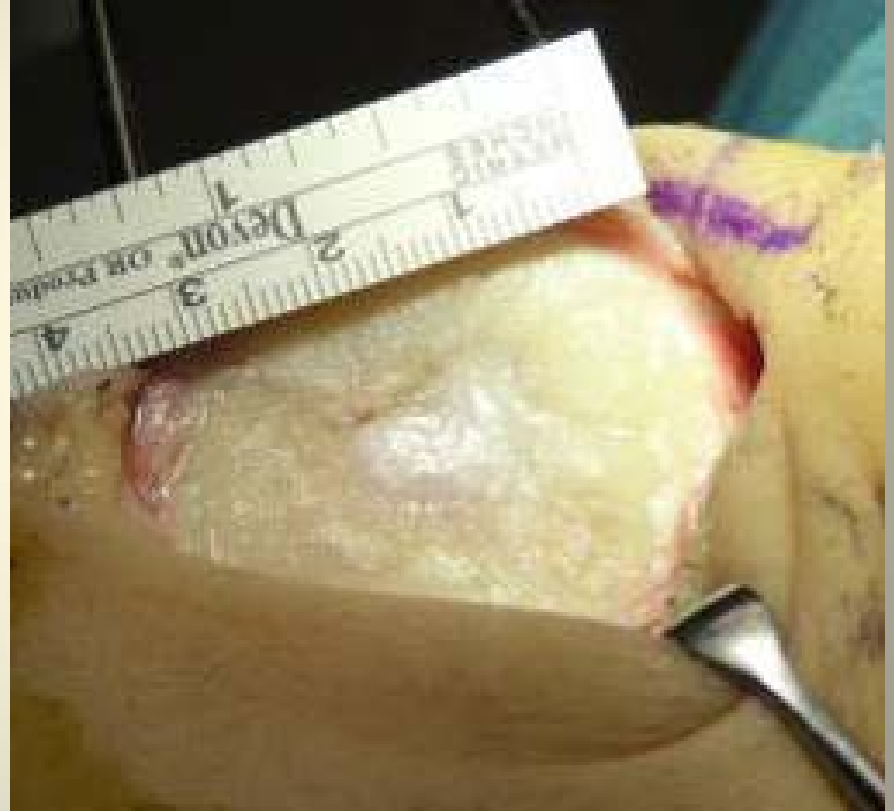Broad Consideration for Geometry of Cartilage Restoration

- Cellular/semirigid scaffold based therapies
 - NO size matching challenges for supply biomaterial, minimal contour challenges
 - Rigid scaffolds, easy to use, flat, no radius of curvature
 - Efficacy, durability, rehab and healing challenges
- Osteochondral Allograft
 - Transplanting healthy hyaline cartilage with intact subchondral bone
 - Long lasting, outstanding pain relief
 - Relatively easy surgery, predictable recovery, excellent outcomes
 - Limited availability and high cost
 - Geometrically challenging to match



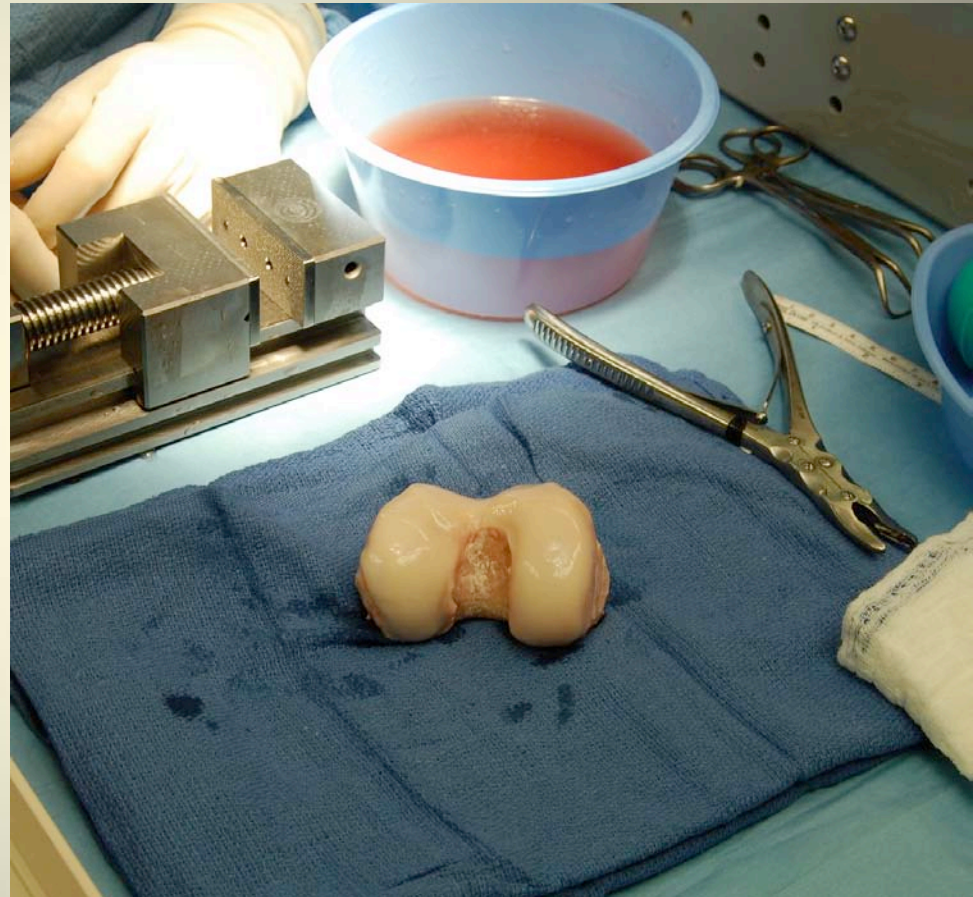
Geometric Challenges- OCA

- Variable concavity/depth of Trochlea
- Radius of curvature, concave and convex, 3D both Trochlea and Patella
- Size of patellar facets
- Convergence of cylinders (OCA) in patella
- Height of patellar ridge
- Thickness of cartilage



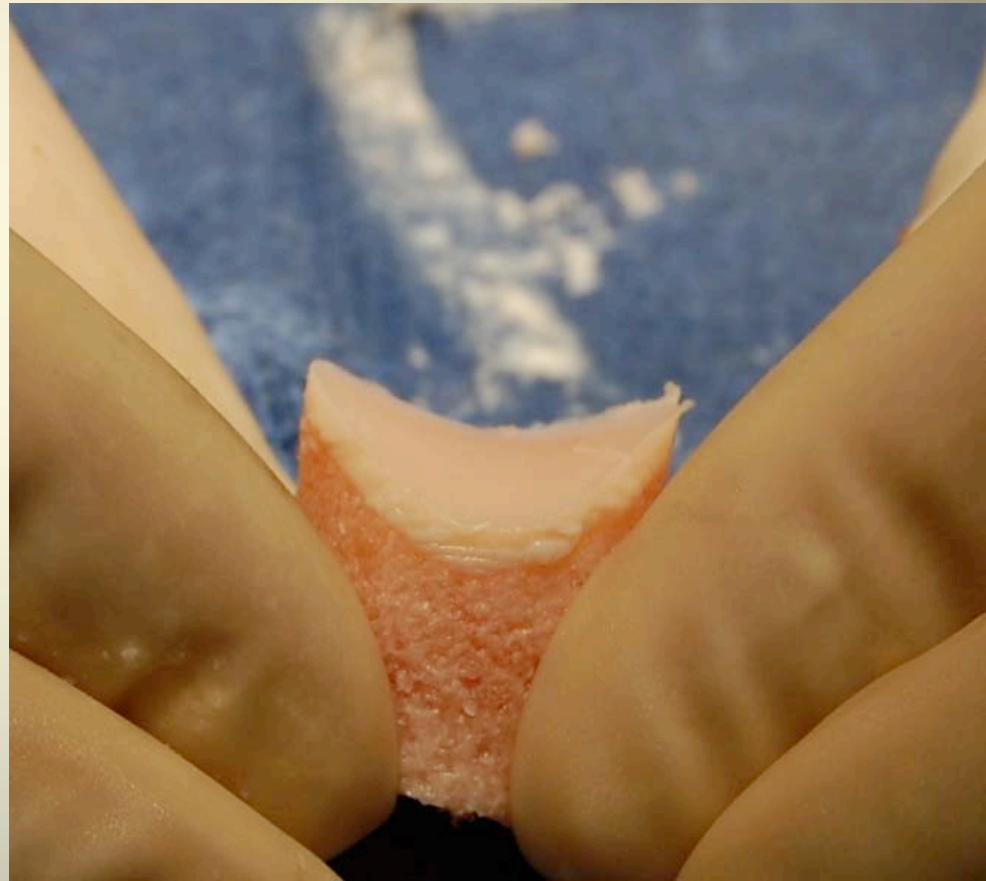
Donor Issues - OCA

- Grafts are fresh stored
- Maintained hypothermically in nutrient solution for 3-6 weeks while donor and graft microbial screening and testing takes place.
- Limited processing of Patellae takes place because of economic pressure to generate BTB grafts for ACL reconstruction. Each Patella could potentially yield 2 or 3 BTB grafts.



Donor Issues - OCA

- Donors typically from young accident victims or tragic deaths
- Limited geometrical data available about donor
- No MRI or CT
- Digital photo
- Linear dimensions of graft
- Scaling- Tibial width




Current Graft Data Sheet

(medial to lateral articulating surface)

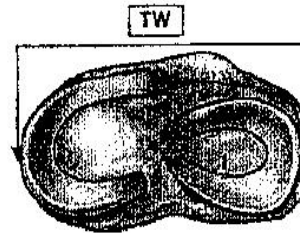
TW= Max. width 7.4 cm

No visual imperfections

COMMENTS: * Binned w/007 *



(Indicate Imperfections)



Initial: EM
Date: 6/21/11

OK
AM
6.21.11

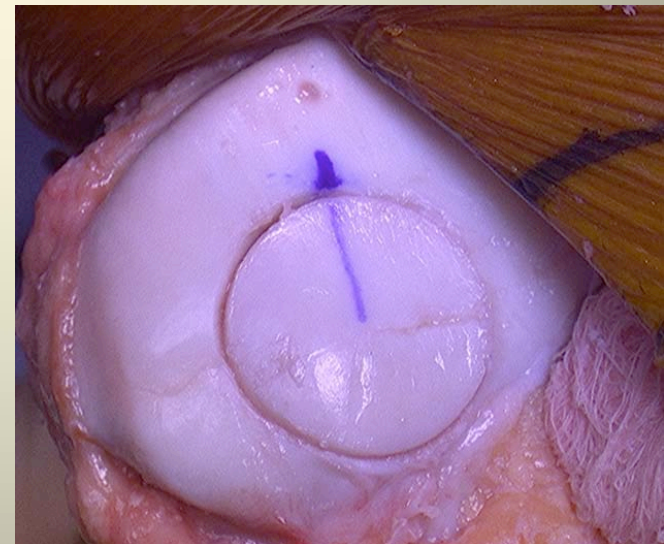
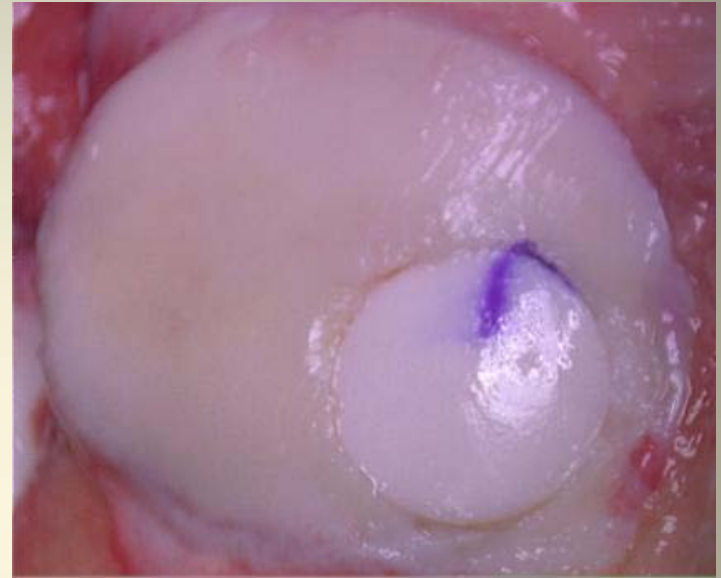
Clearly a paucity of data....

OCA Donor

- What we currently know
 - Age, sex, date of death, Tibial Width
- What we would really like to know:
 - FTG: inter-eminence distance, depth of groove
 - Patellar geometry:
 - Prox-Distal length
 - Med-Lat length
 - Medial facet length
 - Lateral facet length
 - Thickness data could yield indicator of radius of curvature, or height of ridge

Scenarios for OCA of PFJ

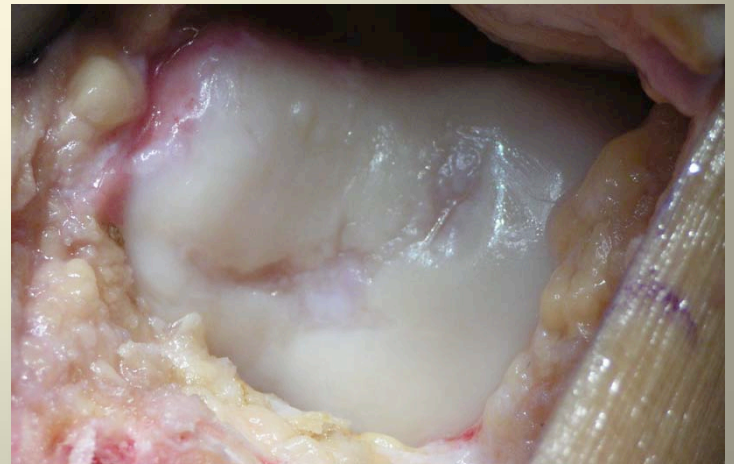
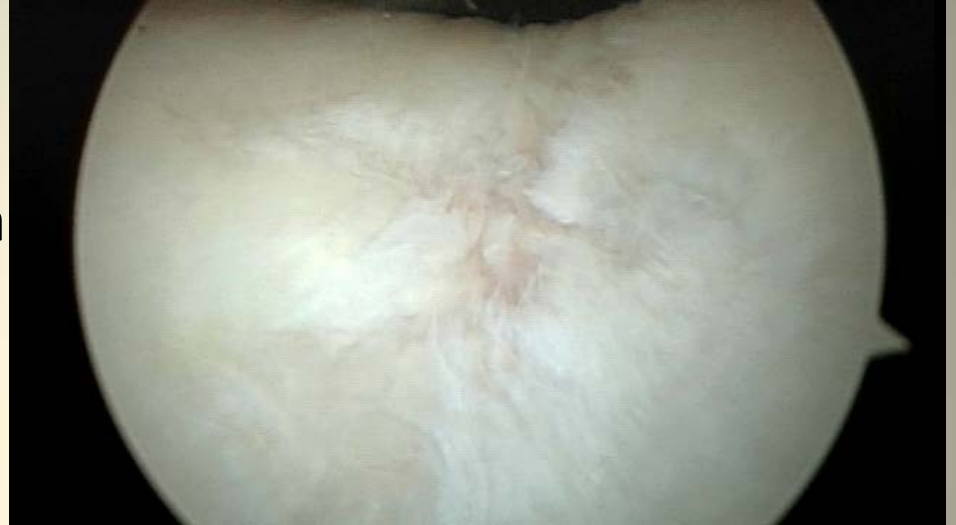- Small Isolated Patella Defect
 - Easiest scenario with simplest geometry
 - Facets relatively flat, easy match for size
- Large Isolated Patella
 - Cylinder graft, usually single plug
 - Dual Consideration-
 - Size of plug
 - Morphology or Topography if facet involved
 - Key: Is donor big enough?
 - Matching: Know defect size, then...
 - Donor AP and ML measurements of total patella and facet data can yield appropriate match



Scenarios for OCA of PFJ

Isolated FTG defect

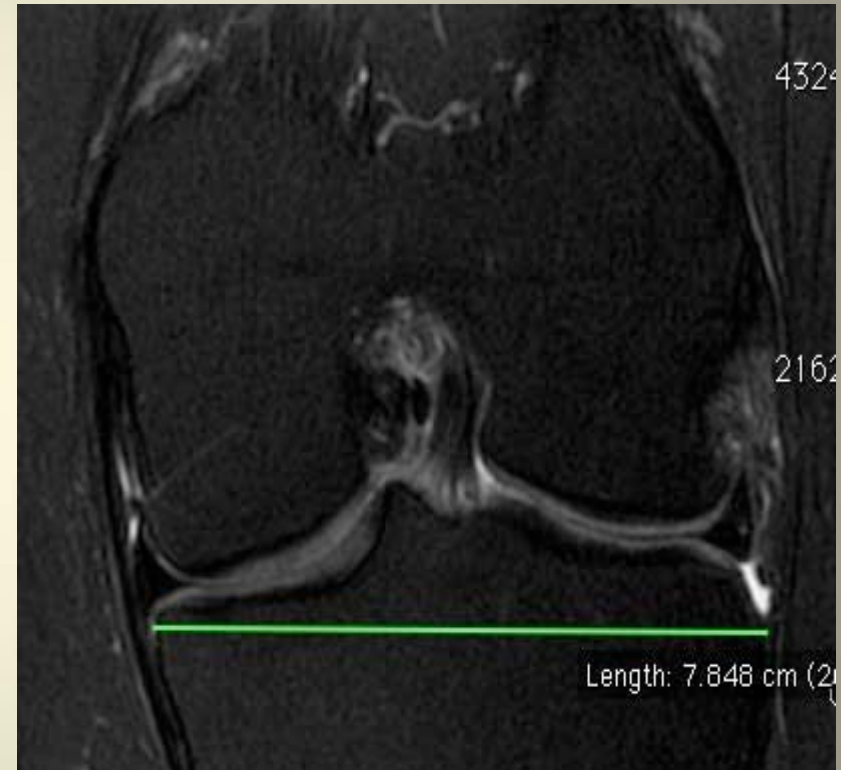
- Small defect:
 - Can usually match easily a typical defect is central in FTG and small plugs with any concavity usually suffice
- Large defect:
 - Want to match size and morphology, bigger challenge.



Scenarios for OCA of PFJ

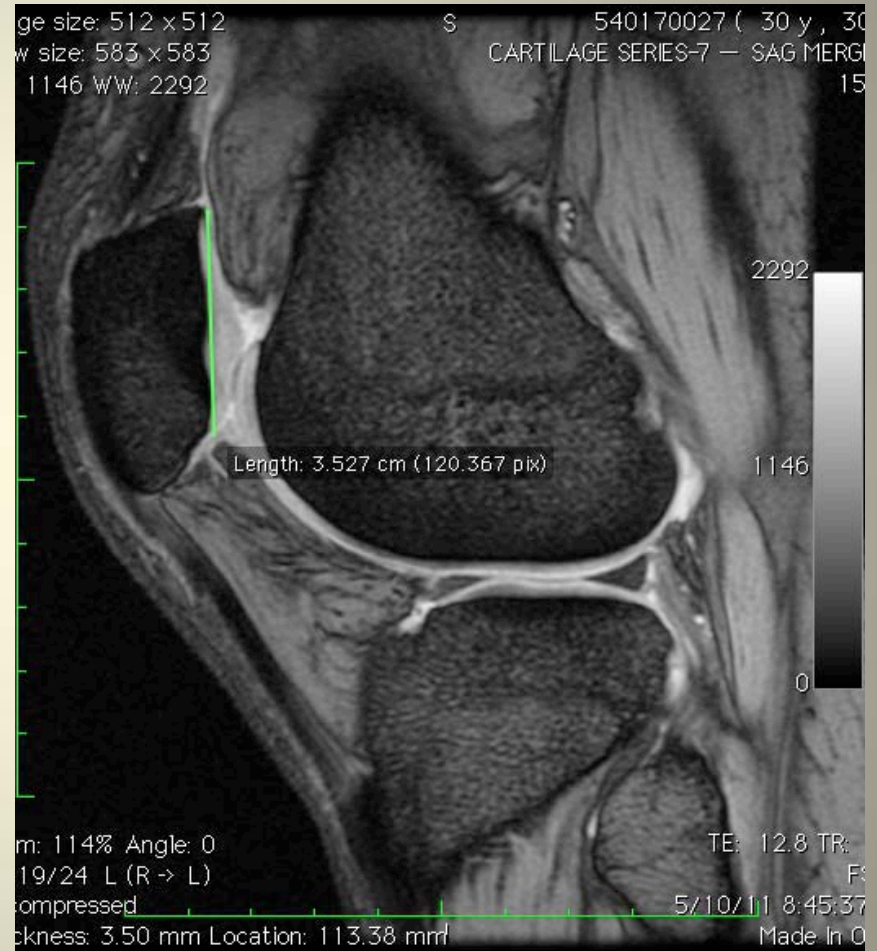Bipolar, including shell grafts

- These are supplanting for the ambient anatomy
- Sizing consideration merely to scale, not really topographic challenge
- Scale within 5mm+/- on Tw should suffice
- Essentially, just need to be relatively close on size/scale



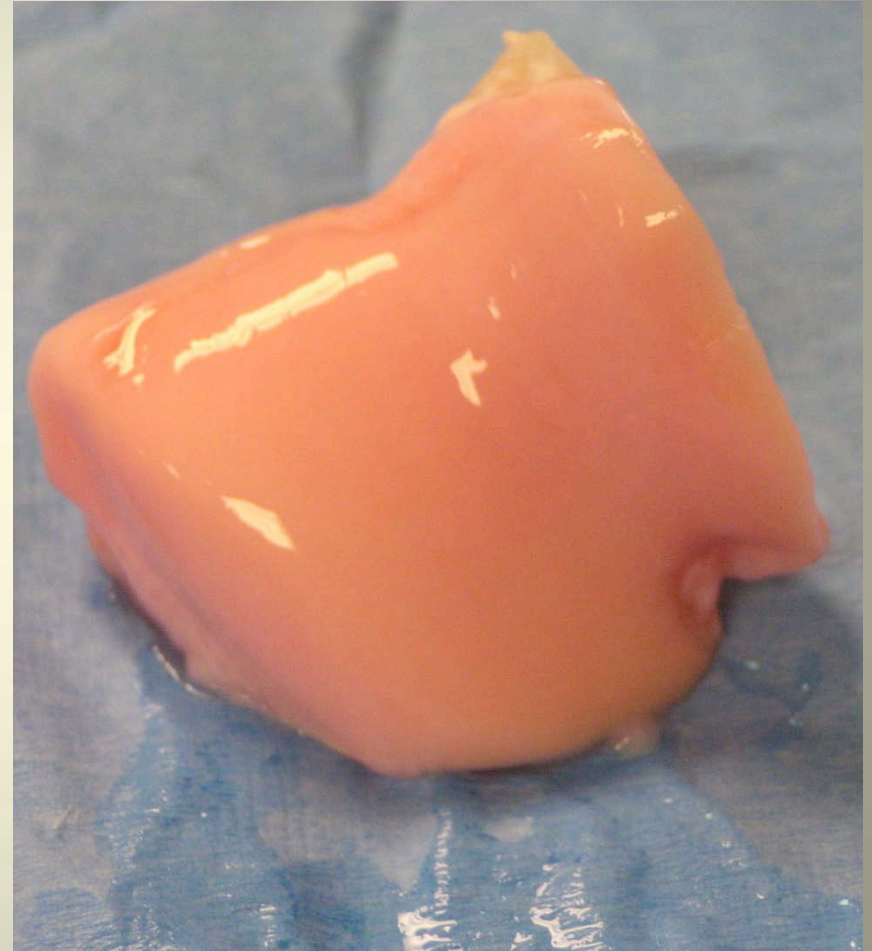Recommendations for OCA Sizing of PFJ

- Patient/recipient
 - Scope measurements of defect
 - Scaling – Tw
 - Easily gotten from any MRI
 - CT or MRI
 - Patella dimensions
 - AP-ML of patella
 - Facet- height(thickness) and dimensions



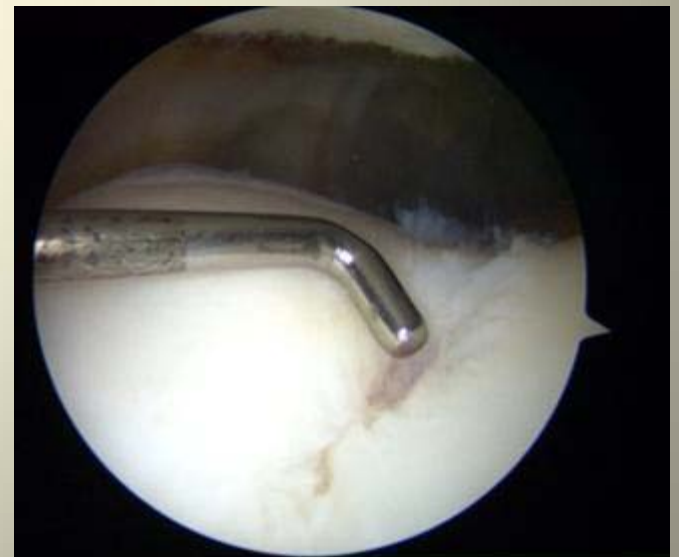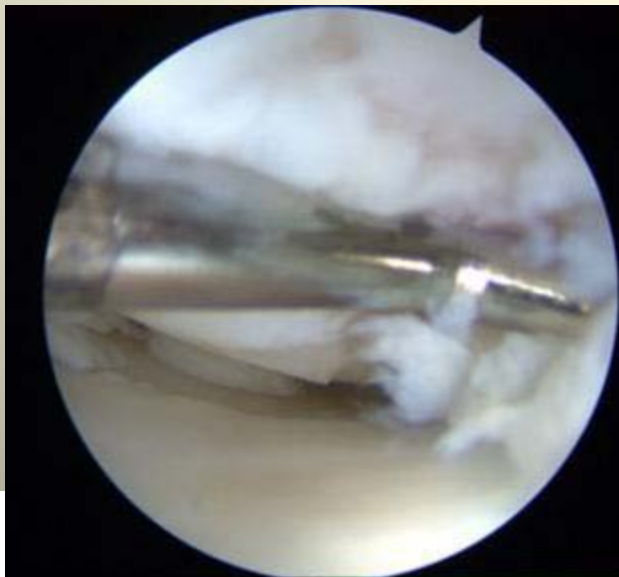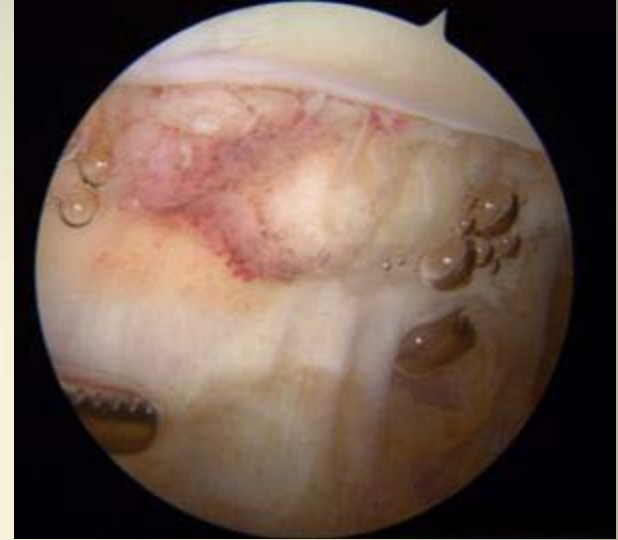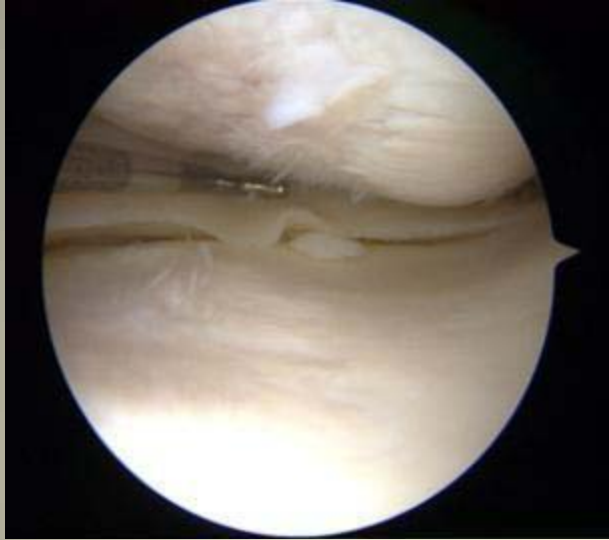
Recommendations for OCA Sizing of PFJ

- Donor
 - Patella
 - Width, height, thickness
 - Scaling, Tw
 - Facet dimensions to ridge
 - FTG
 - Intercondylar distance
 - Depth of groove
 - Scaling, Tw

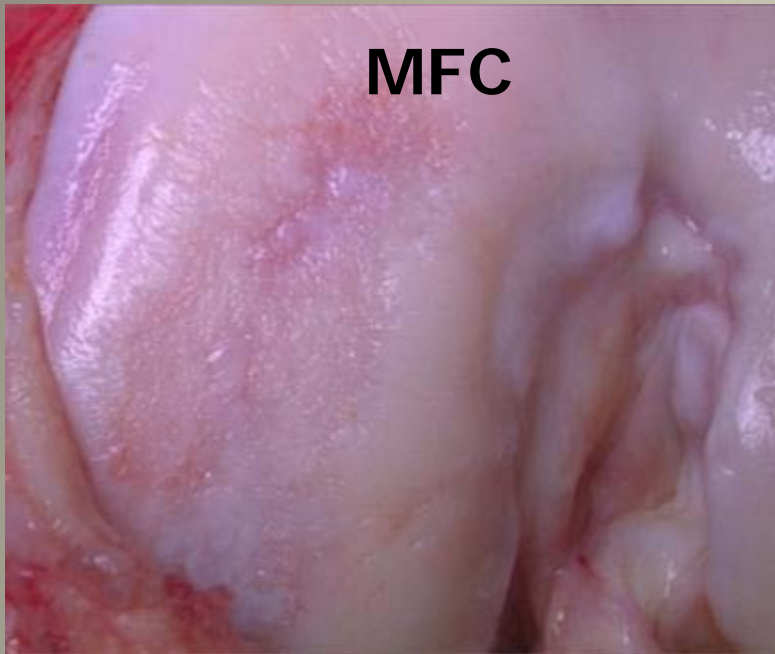


Cartilage case for later discussion

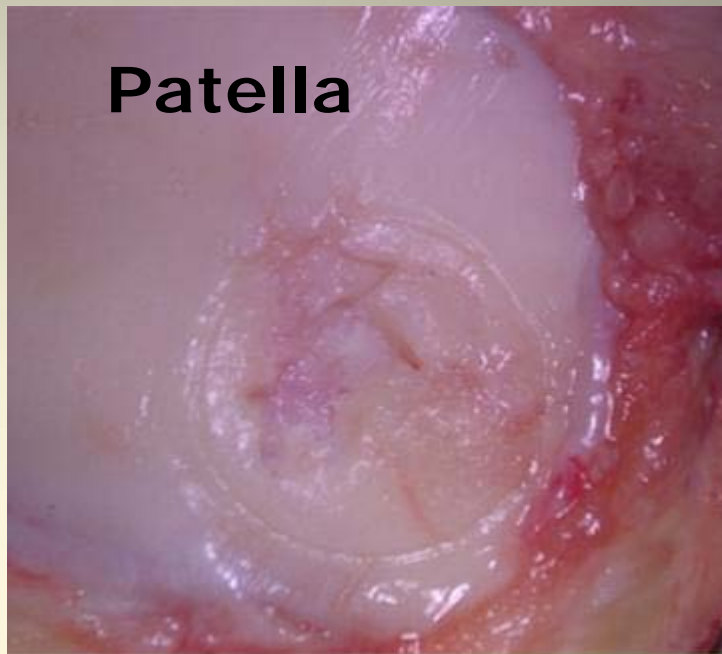29 year old firefighter



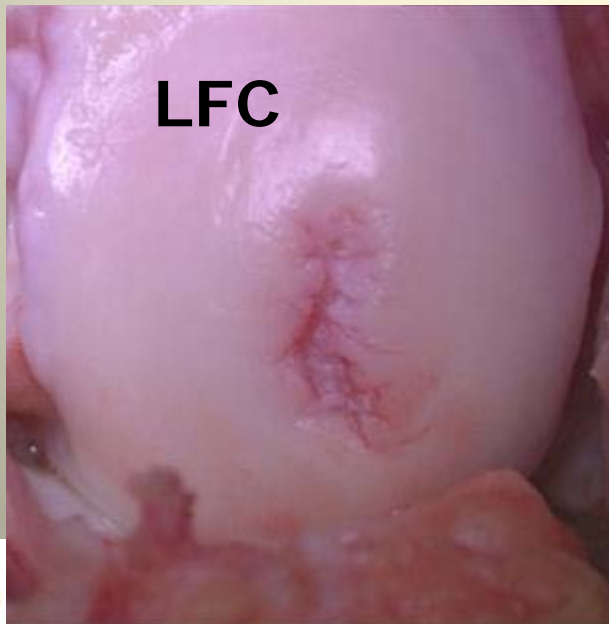
MFC



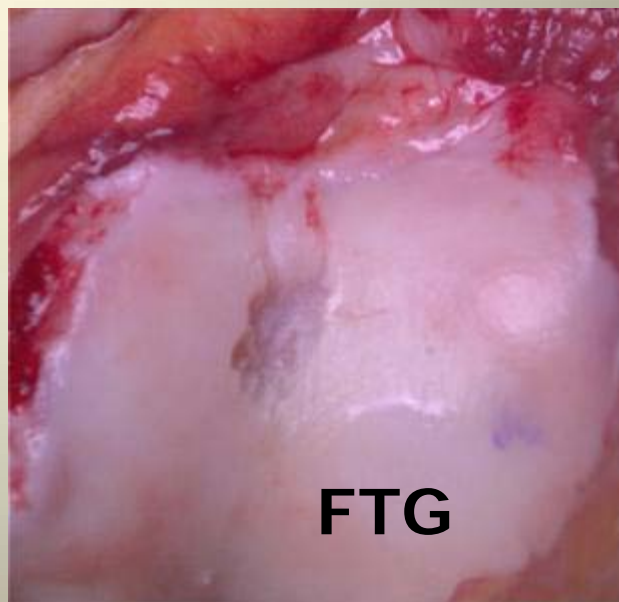
Patella

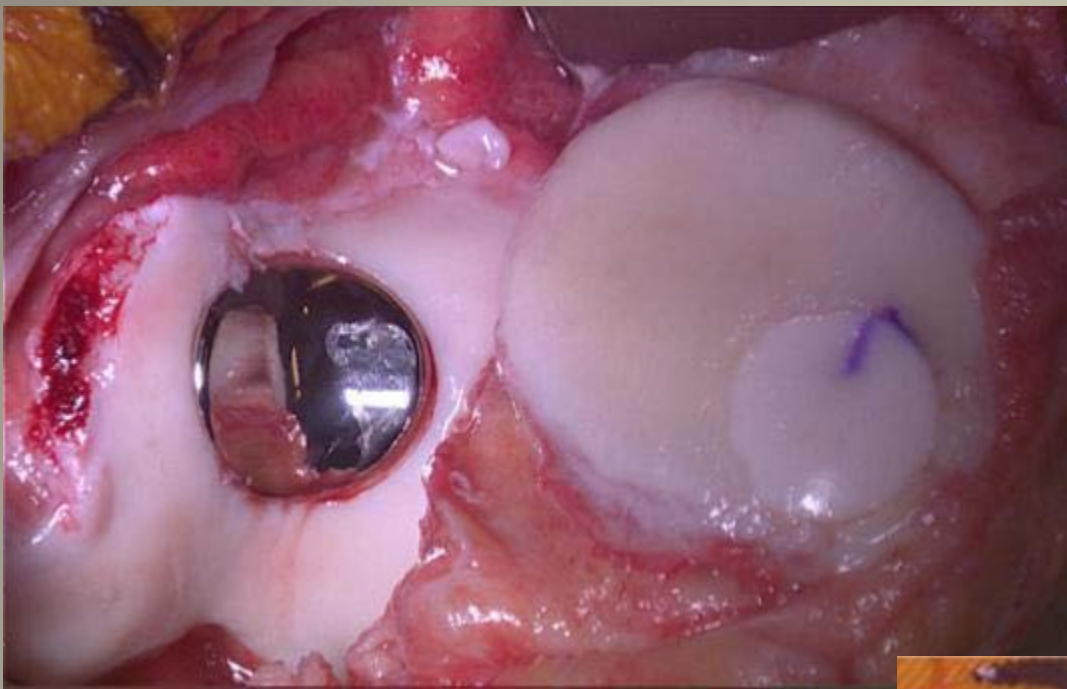


LFC

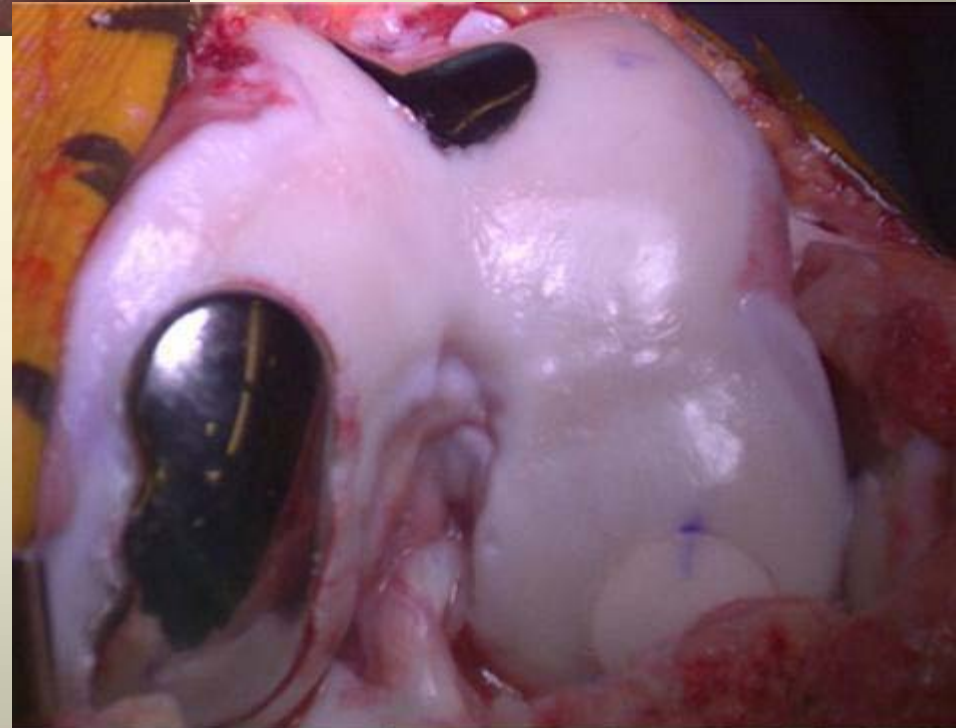


FTG





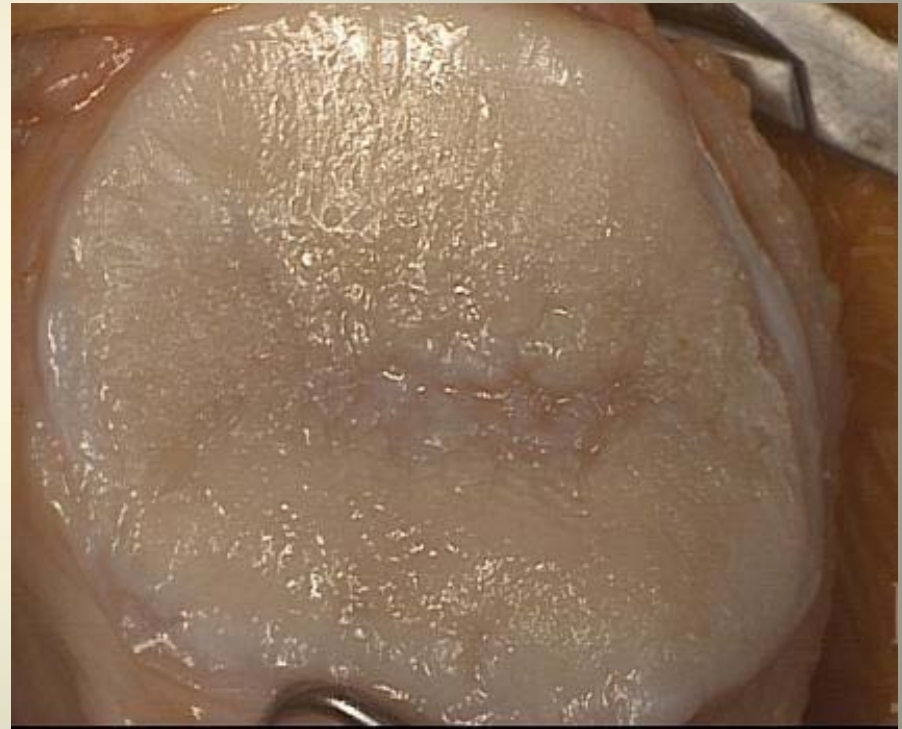
- 6 wks post op back at work light duty
- 12 wks post op full RTW as firefighter
- 2 yrs post op



Biologic or Prosthetic Resurfacing ????

Key decision making point

- Multifactorial decision
 - **Lesion/Cartilage nearby**
 - Patient Factors
 - Age (biological)
 - Comorbidities
 - Joint Status
 - Resources



32 year old mom and former ski racer

Thank you
phildavidsonmd@gmail.com

